Journal of Plastic, Reconstructive & Aesthetic Surgery (2006) **59**, 571–579

JPRAS
An International Journal of Surgical Reconstruction
www.JPRASurg.com

Breast reconstruction with the deep inferior epigastric perforator flap: History and an update on current technique

Jay W. Granzow[a], Joshua L. Levine[b], Ernest S. Chiu[b], Robert J. Allen*[,b]

[a]*UCLA Division of Plastic and Reconstructive Surgery 200 UCLA Medical Plaza, Suite 465 Los Angeles, CA 90095-6960, USA*
[b]*Section of Plastic Surgery, Louisiana State University Health Sciences Center, 4429 Clara Street, Suite 440, New Orleans, LA 70115, USA*

Received 18 May 2005; accepted 1 January 2006

KEYWORDS
Breast reconstruction;
Perforator flap;
Microsurgery;
DIEP;
SIEA

Summary Perforator flaps allow the transfer of the patient's own skin and fat in a reliable manner with minimal donor site morbidity. For breast reconstruction, the abdomen typically is our primary choice as a donor site. The deep inferior epigastric perforator (DIEP) flap remains our first choice as an abdominal perforator flap and has become a mainstay for the repair of mastectomy defects. It allows the transfer of the same tissue from the abdomen to the chest for breast reconstruction as the TRAM flap without sacrifice of the rectus muscle or fascia. We discuss our current techniques and specific issues related to the surgery. We present the results of 1095 cases of free tissue transfers from the abdomen for reconstruction of the breast.
© 2006 The British Association of Plastic Surgeons. Published by Elsevier Ltd. All rights reserved.

Breast reconstruction is a vital component of the overall treatment plan of breast cancer patients. Surgical breast reconstruction is not only desired by most patients, but is recommended by law in many countries. It is being performed with increasingly sophisticated techniques to optimise the appearance, and feel of the reconstructed breast limit donor site morbidity and provide a long term result. The use of autologous tissue allows the reconstruction of a breast which looks and feels most like a normal breast. The advent of perforator flaps now allows for minimal donor site morbidity and good flap durability.

The abdomen is an ideal source of tissue for breast reconstruction. Most patients who develop breast cancer are at an age when they also have excess skin and fat overlying the abdomen. The fat is typically soft and easy for the surgeon to shape and closely approximates the feel of a normal breast. In addition, an added bonus of an abdominal donor site for most patients is the improved abdominal contour after flap harvest which approximates that

* Corresponding author. Tel.: +1 504 894 2900; fax: +1 504 894 2901.
E-mail address: boballen@diepflap.com (R.J. Allen).

S0007-1226/$ - see front matter © 2006 The British Association of Plastic Surgeons. Published by Elsevier Ltd. All rights reserved.
doi:10.1016/j.bjps.2006.01.004

of an abdominoplasty or 'tummy tuck' while minimising donor site morbidity.

The deep inferior epigastric perforator (DIEP) flap is a central component in the state-of-the-art practice of breast reconstruction and usually our first choice of flap from the abdomen. It allows the safe transfer of soft tissue from the abdomen for the construction of a new breast without the sacrifice of rectus muscle or fascia.

The DIEP and other perforator flaps trace their origins back to the work of Stuart Milton in the 1960s. At that time, wound closure flaps were random pattern flaps based on the geometric principle of a length to width ratio of approximately 1.5–1. Using a porcine model, Dr Milton in 1970 and 1971 demonstrated that flaps of a much greater length to width ratio could be elevated safely when based on a known underlying vessel.[1,2] This led to the concept of the axial pattern pedicle flap, which was first reported in MacGregor and Jackson's description of a groin flap in 1972.[3] Later, in 1982, Hartrampf would use the pedicle flap concept to transfer abdominal tissue to the chest for breast reconstruction using the superior epigastric artery and the rectus abdominus muscle as a carrier.[4] This flap came to be known as the transverse rectus abdominus myocutaneous, or TRAM, flap.

In 1973, the term 'free flap' was used by Taylor and Daniel to describe the distant transfer of an island flap by microvascular anastomosis.[5,6] Taylor and Daniel further expanded upon their work in 1975 with a detailed anatomical description of many of the more common free flap donor sites in use today.[7] In 1979, Holstrom described the use of the equivalent of a free TRAM flap with his description of a "free abdominoplasty flap" for breast reconstruction.[20]

Attempts were made to reduce the muscle bulk removed and to limit the donor morbidity.[8] The concept of donor site muscle sparing techniques was reported, as represented by Elliott with the split latissimus[9] and by Feller with the partial rectus abdominus muscle transfer.[10] This idea was further refined by Koshima who used the skin territory overlying the rectus abdominus muscle for reconstruction of the mouth and groin.[11] The flaps were based on a single paraumbilical perforating vessel from the deep inferior epigastric artery, and were composed of skin and fat only.

Independently, Allen and Treece in 1992[12] successfully performed the first DIEP flap for breast reconstruction by transferring the abdominal skin and fat from the same donor area of a TRAM flap while sparing the underlying rectus abdominus muscle. This provided essentially the same soft tissue for reconstruction while significantly reducing the morbidity to the abdominal wall, thereby minimising donor site morbidity and pain while shortening recovery time.[13–15]

Indications

Most women who have had or will have mastectomies for breast cancer are possible candidates for a DIEP flap. In addition, this flap may be used for women requiring additional breast tissue for reconstruction of defects such as a congenital breast deficiency, a lumpectomy defect or for autologous breast augmentation.[16]

Absolute contraindications specific to abdominal perforator flap breast reconstruction in our practice include history of previous abdominoplasty or abdominal liposuction, or active smoking (within 1 month prior to surgery). Relative contraindications include large transverse or oblique abdominal incisions. Care must be taken in patients with previous appendectomy scars. In our practice, we have encountered a case where the right deep inferior epigastric artery pedicle had been divided during the patient's appendicectomy many years previously.

We prefer to have the patient complete any radiation therapy to the chest prior to surgical breast reconstruction. While the perforator flaps usually tolerate radiation well, a superior long-term result is obtained typically in reconstructions performed after rather then before chest wall radiation. This spares the flap the damaging effects of radiation and allows the replacement of any thick and stiff irradiated chest wall skin and its replacement with soft and unirradiated abdominal skin and soft tissue.[17]

Anatomy

Like a TRAM flap, the DIEP flap is based on the deep inferior epigastric artery and vein. Two rows of perforating arteries and veins penetrate the rectus muscle on each side of the abdomen to provide the blood supply for the overlying skin and fat (Fig. 1). The deep inferior epigastric artery is typically between 2 and 3 mm in diameter and the accompanying veins are between 2 and 3.5 mm in size.

In contrast to a TRAM flap, however, no rectus muscle or fascia must be sacrificed. Instead, the perforating vessels, which supply the overlying skin and fat are carefully followed through the rectus muscle to their origins from the deep inferior epigastric vessels. The rectus muscle itself is spared

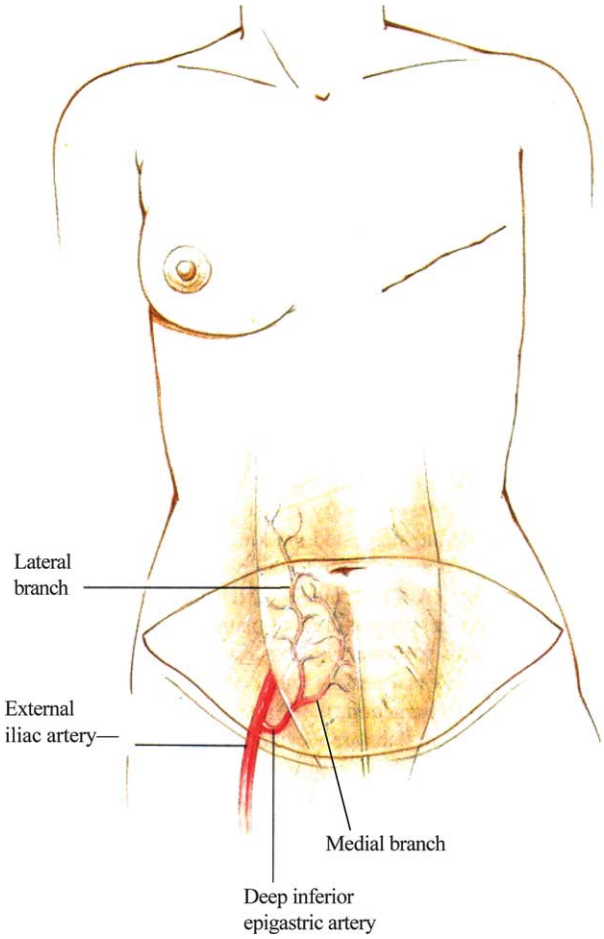

Figure 1 Typical preoperative marking on the lower abdomen of a patient undergoing breast reconstruction using the DIEP free flap.

and atraumatically spread apart in the direction of the muscle fibres during the dissection (Fig. 2).The internal mammary or thoracodorsal vessels are used as recipient vessels (Figs. 3 and 4).

Current surgical technique

The patient is seen in the office one day prior to surgery. The surgical plan is reviewed with the patient, and any remaining questions are answered.

Standard abdominoplasty markings are made in the sitting or standing position. The side of the abdomen contralateral to the side to be reconstructed is preferred, as this provides for a synchronous two team approach. Because a very long pedicle may be harvested, insetting typically is not a problem with either an ipsilateral or contralateral pedicle. Flaps are marked approximately 12 cm high at the midline and extend approximately 22–24 cm laterally from the midline. Then, with the patient in a supine position, a hand held audible Doppler probe is used to identify the main perforators of the medial and lateral branches of the deep inferior epigastric artery. The superficial inferior epigastric artery and vein are likewise located with the Doppler probe and marked.

The side of the abdomen contralateral to the side to be reconstructed is preferred. We prefer to use the thicker medial and paraumbilical abdominal fat for reconstruction of the inferomedial breast with the lateral part of the flap inset towards the axilla. A DIEP flap based on multiple perforators will have a pedicle which naturally will lay best toward the internal mammary recipient site in a contralateral flap. If the thoracodorsal vessels are used as recipients, the geometry of an ipsilateral DIEP flap would be advantageous. However, most ipsilateral or contralateral DIEP flaps can be inset without difficulty in either case because the long length of the vascular pedicle allows significant freedom in flap insetting.

On the chest, the midline and the inframammary crease on both sides are marked. For patients undergoing immediate breast reconstruction, suggested skin markings for the surgical oncologist are drawn on the breast, which include marks around the nipple areolar complex and previous biopsy site. For patients with large breasts, a pattern is marked which is similar to those of a vertical scar breast reduction. For patients with smaller breasts, a circle around the nipple areolar complex with a small inferior or lateral extension may suffice (Figs. 5 and 6).

The operating room table is turned 180° to allow the surgeons to sit comfortably with legs under the table during the microvascular anastomosis. Under general anaesthesia, the patient is prepped and draped from the chin to the upper thighs. The ipsilateral arm may be prepped and included in the field if an immediate sentinel node biopsy or axillary node dissection is to be performed in addition to the mastectomy. For an immediate breast reconstruction, dimensions and weight of the mastectomy specimen are recorded.

A two team approach is used, with simultaneous raising of the flap and preparation of the recipient vessels. The internal mammary artery (IMA) and vein (IMV) are used in over 90% of our cases while the thoracodorsal vessels are our second choice. The internal mammary vessels are noted to be of good quality and calibre in most cases. We use the thoracodorsal vessels, which are typically not as robust, for reasons of flap geometry or ease of flap insetting rather than insufficiency of the internal mammary vessels.

We approach the IMA in the second or third interspace. Occasionally, a large perforating artery

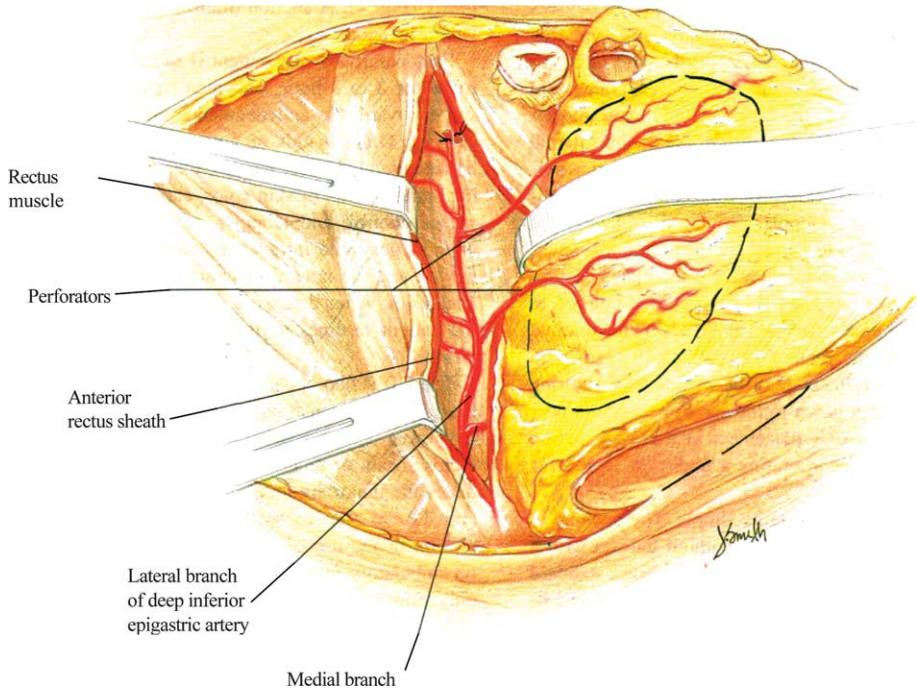

Figure 2 Perforating vessels of the lateral branch of the deep inferior epigastric artery are visible coursing through the rectus sheath.

and vein from the internal mammary vessels may be found and these vessels used as the recipients in the chest. The IMA and IMV are usually between 2.5 and 3 mm in size. Sometimes a second vein between 1.5 and 3 mm may be encountered. In the case in the narrow interspace, a small portion of the rib cartilage above and below may be removed for better exposure and insetting of the pedicle.

When we perform a DIEP flap, the superior and inferior skin incisions are made and the superficial inferior epigastric vessels are first approached. If these are found to be of significant size and quality, they are followed down to their origin from the superficial femoral artery and an SIEA flap is performed instead. Often only the superficial inferior epigastric vein is present of sufficient size and this is dissected free for several centimetres. This can be used as a backup for the venous drainage of the flap if venous congestion be present after the anastomosis is performed in the chest. In

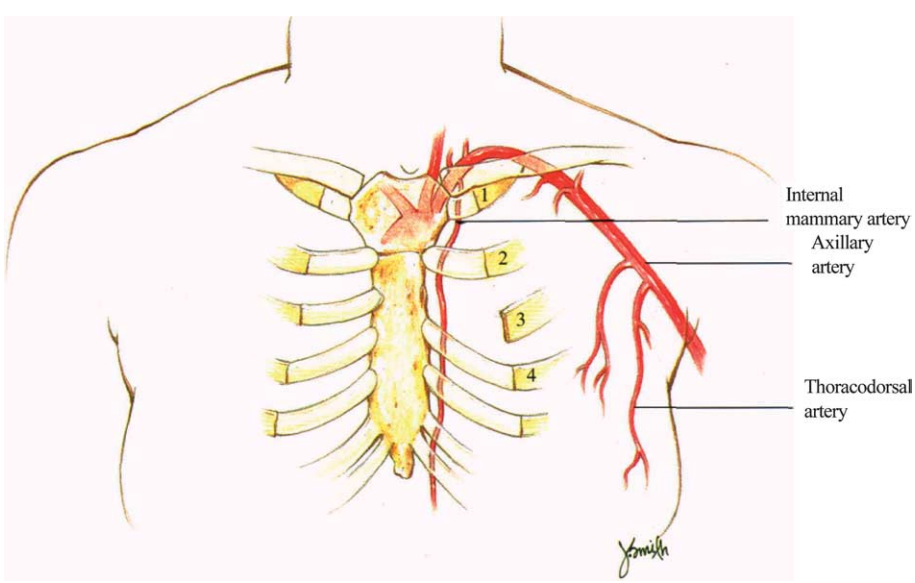

Figure 3 Isolation of the internal mammary artery provides an excellent recipient site.

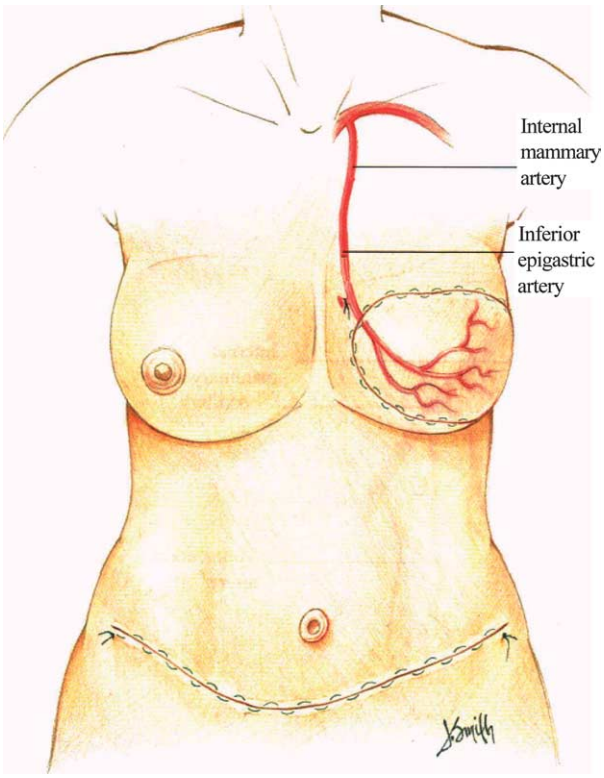

Figure 4 Recipient and flap arteries after anastomosis and flap inset.

our experience, this vein can prove invaluable in the rare case where congestion is present due to insufficient drainage through the deep system.

The abdominal skin island is carefully elevated from lateral to medial until the lateral row of perforators is encountered. The lateral perforators are carefully inspected. If a large lateral perforator is found, the flap may be based on this vessel. Additional perforators in the same row may also be dissected and included with the flap for additional perfusion. If no large lateral row perforators are found, the medial row is approached in a similar fashion. If no dominant single perforators are found, two or more smaller perforators in the same lateral or medial row may be taken to perfuse the flap. In cases where more than one large perforator is present, the perforator with a more central location to the proposed flap is utilised. In our experience, approximately 25% of flaps are based on one perforator, 50% on two perforators and 25% on three or more perforators.[18]

Once the appropriate perforators are chosen, the anterior rectus sheath is opened around the perforators and the vessels are carefully dissected down through the rectus muscle to the deep inferior epigastric artery and vein. The muscle is spread apart in the direction of the fibres and care is taken to identify and preserve any intercostal nerves innervating the medial aspect of the muscle, which might cross the pedicle. Dissection continues until the pedicle is of sufficient length, typically eight to 10 cm long, and the vessels are a sufficient caliber to match the recipient vessels in the chest. High power loupe magnification and careful microsurgical technique are essential during this dissection.

Pure sensory nerves which innervate the flap skin paddle typically run with the perforators and may also be dissected free for anastomosis into divided recipient sensory nerves in the chest.

Once the recipient vessels are ready, the anterior surface of the pedicle vessels at their origin are marked with a surgical marker for pedicle orientation in the chest. The artery and then veins of the pedicle are ligated and the pedicle slid out underneath any crossing intercostal nerves. The flap is then weighed and transferred to the anterior chest wall. Great care is taken to lay the pedicle of to the recipient vessels without any twists or kinks in the vessels. While vascular problems with the flaps occur rarely, many of the venous difficulties that do occur result from a twist or a kink of the pedicle. Temporary stay sutures are placed in the flap and the operating microscope is brought into position.

Under magnification, the anterior surface of the recipient artery and vein are also labelled with a surgical marker and the larger vein is ligated distally. An anastomotic coupling device is used to connect to the recipient and flap veins (Microvascular Anastomotic COUPLER System, Synovis, www.synovismicro.com). A coupling device makes the anastomosis easier and faster, and has the additional benefit of stenting the vein open after the vessels are joined. Typically, the arterial anastomosis is performed with a nylon 9/0 suture. In the case of a good size match between the flap and recipient arteries, a running suture is employed. Otherwise, interrupted 9/0 or 10/0 nylon sutures are used. After the anastomosis is complete, the flap is checked for bleeding and capillary refill. In the case of a small skin island or in a patient with dark skin where skin evaluation may be difficult, an implantable Doppler probe (Cook-Swartz Doppler Flow Probe; Cook Vascular Incorporated, www.cookvascular.com) is used to monitor a continuous arterial and/or venous signal.

The abdominal fascia is closed and securely tied with running size 0 PDS suture. Mesh or other synthetic materials are not required for the abdominal wall closures. The edges of the umbilicus are tacked down to the fascia with 2/0 Vicryl suture. The upper abdominal flap is elevated, the patient flexed and the wound closed in layers over two closed suction drains. Care is taken to approximate Scarpa's fascia with 2/0 interrupted

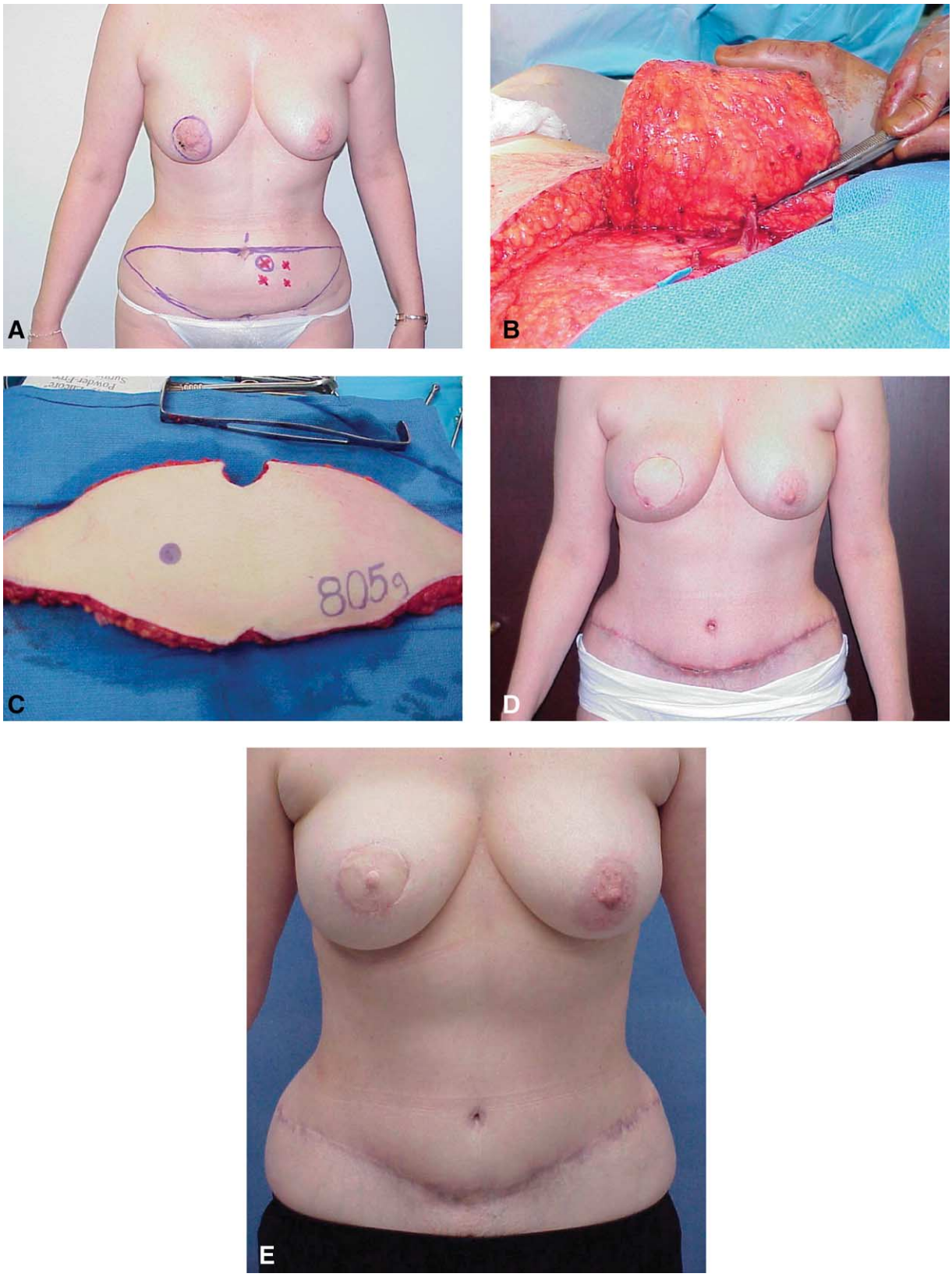

Figure 5 (A) Preoperative markings for patient with right breast carcinoma. (B) DIEP flap raised on perforator. (C) DIEP flap after harvest. (D) Patient 3 months after initial flap transfer. (E) Patient 3 months after nipple construction.

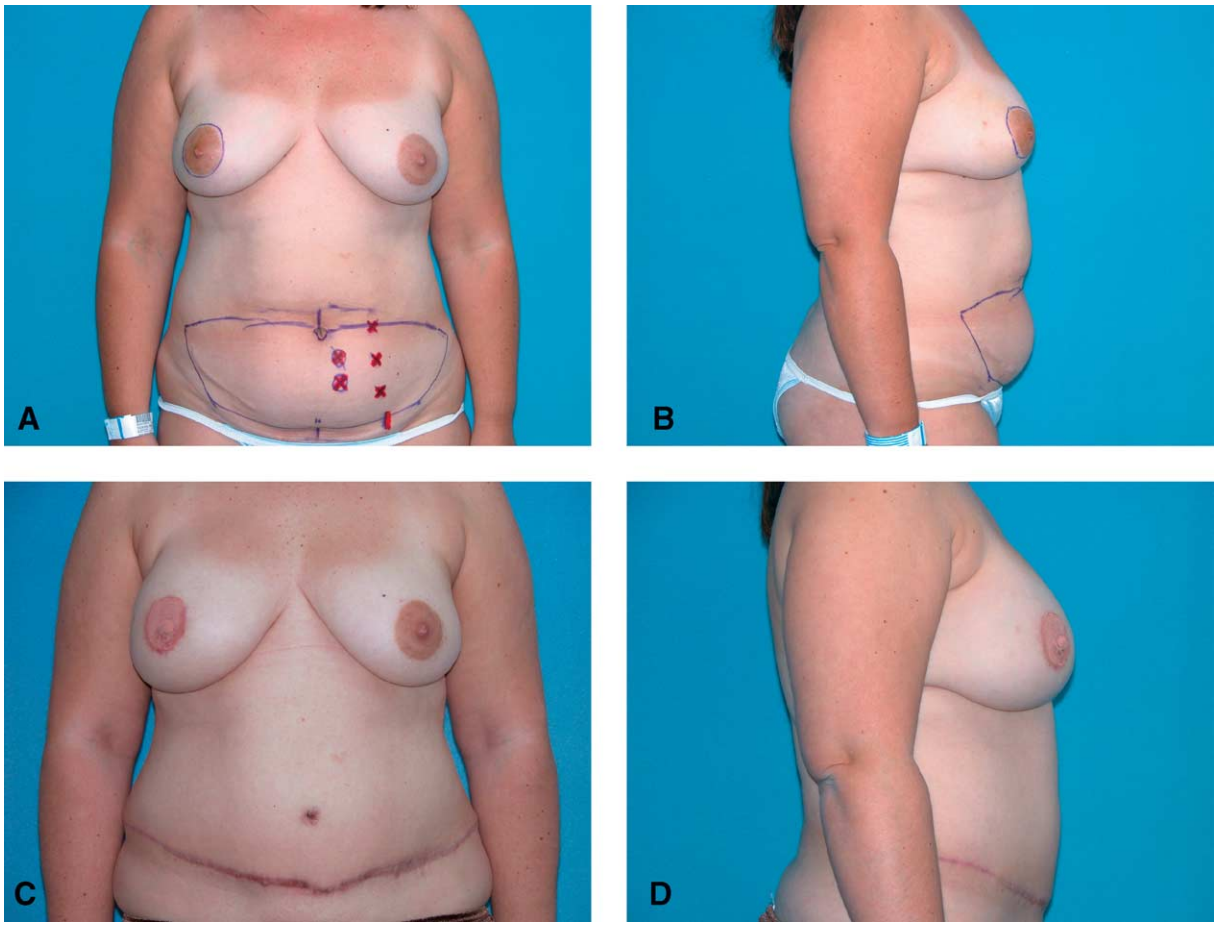

Figure 6 (A) and (B) Preoperative views of patient with right breast carcinoma for mastectomy with DIEP flap reconstruction. (C) and (D) Patient approximately 3 months following second stage procedure, nipple reconstruction and areolar tattoo.

Vicryl sutures. As in an abdominoplasty, the umbilicus is brought out through the abdominal flap and secured in place.

The flap is typically inset with the narrower and more lateral portion of the flap placed up towards the axilla and the thicker, more medial aspect of the flap placed inferiorly and medially. The flap can be further medialised and kept from falling laterally into the axilla by suturing the superior and lateral most parts of the flap to the lateral portion of the pectoralis major muscle. The flap may also be folded under itself inferiorly to provide more natural looking inferior ptosis and fullness for the reconstructed breast. The insetting and closure are performed over a suction drain and great care is used to monitor the integrity of the pedicle during the insetting at the flap at all times. Excess skin is deepithelialised and the flap inset with a visible skin paddle left in place.

During the insetting, all of zone 4 is typically removed, weighed and discarded. We find that the perfusion from a perforator flap usually is sufficient only to carry zones 1–3. Areas of significant or palpable fat necrosis occur in a minority of cases only and these are addressed during the standard second stage revision.

Postoperative care

Postoperatively, the patient is observed in the Surgical Intensive Care Unit overnight and transferred to the ward in the morning of the first postoperative day. As the postoperative pain is significantly less than with a TRAM flap reconstruction,[15] usually oral analgesics are given 1st postoperative day onwards. The patient ambulates on 1st postoperative day and is discharged home on 4th postoperative day.

A second stage revision and nipple creation are performed under local anaesthesia with intravenous sedation in the operating room between 8 and 12 weeks after the initial surgery to further refine and finish the appearance of the breast. Any

revisions at the donor site, such as dog ear removal or liposuction, are also performed at this time.

Total number of patients

Complications are infrequent. In a 10-year retrospective review of 758 DIEP flaps by our unit, 6% of patients returned to the operating room for flap related problems. Partial flap loss occurred in 2.5% while total flap loss occurred in less than 1% of all cases. Problems with the vein or venous anastomosis were almost eight times more likely than problems with the artery or arterial anastomosis. Fat necrosis appeared in 13% of flaps. Seroma formation at the abdominal donor site was approximately 5% and abdominal hernia occurred in 0.7% of cases.[18]

Discussion

In our experience, the DIEP flap has shown to be a safe, consistent and reliable flap for breast reconstruction. The preparation, marking, harvest and inset described above will be sufficient to take care of the majority of patients presenting for breast reconstruction.

On occasion we perform an SIEA flap in a patient instead of a DIEP flap. This usually occurs when the superficial inferior epigastric artery and vein are of sufficient size and calibre to carry the flap, as described above. It is our experience that usually there is an inverse relationship between the sizes of the superficial and deep inferior epigastric systems. The presence of a large superficial artery found early during the flap dissection can be a warning that no one or two or even three dominant perforators will be found in the ipsilateral hemiabdomen of the patient. In a review of 1095 cases performed in just over the last 8 years since we have been performing SIEA flaps as described above, 867 (79%) were DIEP flaps and 228 (21%) were SIEA flaps. Complication rates were similar for both types of flaps, with the absolute rates of donor site seroma and flap fat necrosis being slightly higher for the SIEA flaps and an overall flap loss rate for both flaps approximating 1%. We believe the reasons to be the course of the SIEA dissection through the groin lymphatic bed and the typically smaller and more lateral vascular territory of the superficial system on the abdominal flap, respectively.[19]

Sometimes there is a concern that a patient is too thin or does not have enough tissue in the abdomen for a DIEP flap. In our experience, the tissue found at the abdominal donor site is sufficient for reconstruction of mastectomy defects in most patients. This is true even for most thin patients. While thin patients have smaller amounts of abdominal tissue available for reconstruction, they tend to have smaller breast volumes to replace as well. In a different 8-year review of 172 patients who had both SIEA and DIEP flaps for breast reconstruction, the weights of the harvested flaps averaged approximately 120% of the weights of the mastectomy specimens in immediate reconstructions.[19]

Some patients have more fat in the gluteal region than the abdominal area. In this subset of patients, a gluteal artery perforator (GAP) flap may be used as a first choice for breast reconstruction.

If a further amount of additional volume is needed from the abdomen, a perforator connecting to the deep inferior epigastric vessels on the side opposite the main pedicle may be dissected free on the same flap. This permits the safe use of the entire flap, including the opposite most lateral portion of the flap (zone 4), which is usually trimmed and discarded. The flap is folded onto itself and secured with several deep Vicryl sutures between the layers of Scarpa's fascia as needed. An additional anastomosis between the opposite pedicle and a side branch of the main, ipsilateral flap pedicle is performed first, followed by the standard anastomosis of the main pedicle. The flap is then inset with the folded midline portion inferior at the level of the inframammary fold, and the deep portions deepithelialised according to standard technique.

The placement of an implant behind a DIEP flap reconstruction for additional volume is also possible at a later time.

Our experience with the DIEP flap for autogenous breast augmentation is also increasing. We now find that a lateral incision at the anterior axillary line provides superior access both for ease of flap placement and also easy access to the thoracodorsal vessels as recipients. The entire flap is deepithelialised and buried during the first stage. The flap can be monitored safely with implantable continuous Doppler probes on both the artery and vein.

The question sometimes arises regarding other options for breast reconstruction in the case of a failed flap. In our unit over the last 10 years we have found the reliability of the DIEP and SIEA flaps to be quite high, averaging approximately 98–99%. In the unlikely event of a flap failure, typically we prefer to use another perforator flap, such as a GAP flap, for the reconstruction. In all cases the second perforator flap was successful for the breast reconstruction. This again keeps the donor site morbidities to a minimum. In our opinion it is easier and preferable to address the rare complication of a failed perforator flap breast

reconstruction with minimal donor site morbidity than a successful breast reconstruction flap with a rare complication such an abdominal hernia with or without infected mesh.

The DIEP flap is an excellent choice for breast reconstruction, and is usually the first choice of flap for breast reconstruction in our practice. Over the past 13 years in our practice it has shown to be safe and reliable and provide a breast reconstruction with a superior long-term result with minimal donor site morbidity.

References

1. Milton SH. Pedicled skin flaps: the fallacy of the length: width ratio. *Br J Surg* 1970;**57**:502–8.
2. Milton SH. Experimental studies on island flaps. *Plast Reconstr Surg* 1971;**48**:574–8.
3. McGregor IA, Jackson IT. The groin flap. *Br J Plast Surg* 1972; **25**:3–16.
4. Hartrampf CR, Scheflan M, Black PW. Breast reconstruction with a transverse abdominal island flap. *Plast Reconstr Surg* 1982;**69**(2):216–25.
5. Daniel RK, Taylor GI. Distant transfer of an island flap by microvascular anastomoses. *Plast Reconstr Surg* 1973;**52**: 111–7.
6. Taylor GI, Daniel RK. The free flap: composite tissue transfer by vascular anastomoses. *Aust N Z J Surg* 1973;**43**:1–3.
7. Taylor GI, Daniel RK. The anatomy of several free flap donor site. *Plast Reconstr Surg* 1975;**56**(3):243–53.
8. Hallock GG. Defatting of flaps by means of suction-assisted lipectomy. *Plast Reconstr Surg* 1985;**76**:948–52.
9. Elliott LF, Raffel B, Wade J. Segmental latissimus dorsi free flap: clinical applications. *Ann Plast Surg* 1989;**23**:231–8.
10. Feller AM. Free TRAM. Results and abdominal wall function. *Clin Plast Surg* 1994;**21**(223):232.
11. Koshima I, Moriguchi T, Soeda S, Tanaka H, Umeda N. Free thin paraumbilical perforator-based flaps. *Ann Plast Surg* 1992;**29**(1):12–17.
12. Allen RJ, Treece P. Deep inferior epigastric perforator flap for breast reconstruction. *Ann Plast Surg* 1994;**32**: 32.
13. Futter CM, Webster MH, Hagen S, Mitchell SL. A retrospective comparison of abdominus muscle strength following breast reconstruction with a free TRAM or DIEP flap. *Br J Plast Surg* 2000;**53**:578.
14. Kaplan J, Allen R. Cost-based comparison between perforator flaps and TRAM flaps for breast reconstruction. *Plast Reconstr Surg* 2000;**105**(3):943–8.
15. Kroll S, Sharma S, Koutz C, et al. Postoperative morphine requirements of free TRAM and DIEP flaps. *Plast Reconstr Surg* 2001;**107**:338.
16. Allen R, Heitland A. Autogenous augmentation mammaplasty with microsurgical tissue transfer. *Plast Reconstr Surg* 2003; **112**(1):91–100.
17. Rogers N, Allen R. Radiation effects on breast reconstruction with the deep inferior epigastric perforator flap. *Plast Reconstr Surg* 2002;**109**(6):1919–24.
18. Gill P, Hunt J, Guerra A, et al. A 10-year retrospective review of 758 DIEP flaps for breast reconstruction. *Plast Reconstr Surg* 2004;**113**(4):1153–60.
19. Granzow JW, Chiu ES, Levine JL, Gautam A, Hellman A, Rolston W, et al. Autologous breast reconstruction using the superficial inferior epigastric artery flap revisited. *Plast Reconstr Surg* 2005;**116**(3) [Supplement: 133].
20. Holstrom H. The free abdominoplasty flap and its use in breast reconstruction. An experimental study and clinical case report. Scand J Plast Reconstr Surg. 1979;13(3):423–27.

View publication stats