
Profunda Artery Perforator (PAP) Flap for Breast Reconstruction

Constance M. Chen, Maria LoTempio and
Robert J. Allen

Additional information is available at the end of the chapter

<http://dx.doi.org/10.5772/56332>

1. Introduction

Perforator flap breast reconstruction has strong appeal for many women undergoing mastectomies, but the procedure requires adequate donor site tissue. The most common donor site for perforator flap breast reconstruction is the abdomen, such as the deep inferior epigastric perforator (DIEP) or superficial inferior epigastric artery (SIEA) flap, as most women have adequate donor site tissue, the procedure may be performed in the supine position, and the perforating vessels have a dependable caliber and length. In the past, the second line option was usually the buttock, but the buttock as a donor site had multiple disadvantages – most notably a short vascular pedicle, a deforming donor site defect, and a long operative time due to the need to reposition the patient for harvest and inset. Recently, the posterior thigh has emerged as an excellent donor site for perforator flap breast reconstruction. Indeed, the profunda artery perforator (PAP) flap, which uses the skin and fat of the posterior thigh, has surpassed the gluteal artery perforator (GAP) flap in our practice as the second line donor site for microsurgical breast reconstruction.

The PAP flap for breast reconstruction was originated in 2010 by Dr. Robert J. Allen at the 13th International Course on Perforator Flaps in Mexico City. The first patient was a 52-year-old woman who had undergone previous attempts at breast reconstruction with a failed transverse rectus abdominis muscle (TRAM) flap and a failed implant. She wanted autologous tissue reconstruction, and other options considered for her included the superior gluteal artery perforator (SGAP) flap, inferior gluteal artery perforator (IGAP) flap, and the transverse upper gracilis (TUG) flap. Of note, however, the patient had excess posterior thigh tissue, and she did not want to sacrifice her muscle for breast reconstruction. While posterior thigh perforator flaps based on the inferior gluteal artery or profunda femoris artery had previously been

described in the literature,[1-3] they had not been performed for breast reconstruction. Cadaver studies had demonstrated that the dominant blood supply to the posterior thigh was the posterior perforators emerging from the profunda femoris artery (Figure 1). Given the patient’s history, body habitus, and background work by other surgeons and anatomists, Dr. Allen decided to proceed with the first posterior thigh profunda artery perforator (PAP) flap for microsurgical breast reconstruction.

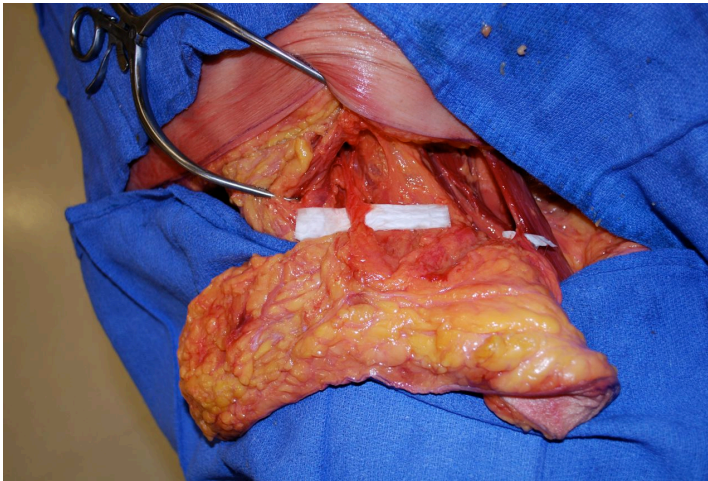


Figure 1. Cadaver studies had demonstrated that the dominant blood supply to the posterior thigh was the posterior perforators emerging from the profunda femoris artery.

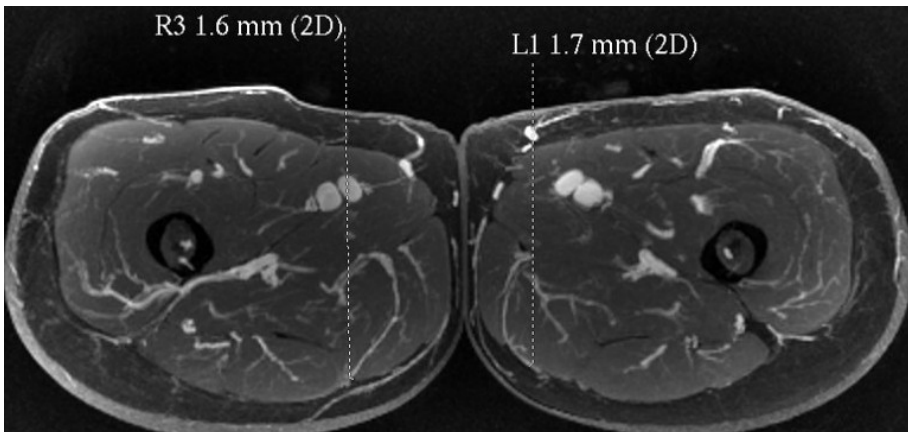


Figure 2. With the midline and inferior gluteal crease as reference points, the largest, most well-placed perforators with the longest vascular pedicle can be identified. In this image, the best perforators have been identified as R3 and L1.

2. Indications

The PAP flap is appropriate for women with insufficient abdominal tissue, previous abdominal liposuction or surgery, a failed TRAM/DIEP/SIEA, pear-shaped body habitus, or who simply have a preference for a non-abdominal donor site. The donor site is the area on the posterior thigh found inferior to the gluteal crease. Excess posterior thigh fat is difficult to address by diet and exercise, and is accentuated in women who are pear-shaped. Even in women who are very thin, there is almost always a “banana roll” of excess skin and fatty tissue located on the back of the thigh below the buttock crease. Removal of the transverse posterior thigh tissue provides contouring and lifting to the thigh area, creates a rounder and more shapely buttock, and does not result in sciatic nerve exposure. The scar is usually concealed within a bathing suit, and the tissue is very soft and pliable.

In breast reconstruction, the PAP flap is coned to create a natural aesthetic breast shape with ample volume for most patients. Even in patients with a BMI < 18, the PAP flap can be successfully used for a very attractive breast reconstruction. The PAP flap skin paddle usually measures 4-7 cm in width and 26 cm in length. Volumes range from 150-900 grams, but in the average patient the volume is between 300-400 grams. Since no muscle is removed, postoperative pain and functional problems are minimized.

3. Preoperative planning

Once the decision has been made to proceed with a PAP flap, each of our patients undergoes a magnetic resonance (MR) or computed tomography (CT) angiogram pre-operatively to determine perforator size and intra-operative course. MR or CT angiography of the pelvis and thigh with contrast is performed in the supine position. Preoperative imaging with MRA or CTA makes it possible to define the intramuscular course of perforators prior to the flap elevation.[4-8] This makes it possible to quickly and accurately identify the size, location, and route of target perforators before the operative procedure. With the midline and inferior gluteal crease as reference points, the largest, most well-placed perforators with the longest vascular pedicle can be identified (Figure 2). Ideally, we choose the medial perforator closest to the inferior gluteal crease and just posterior to the gracilis muscle for ease of dissection in the supine/frog leg position. Three-dimensional MRA reconstruction allows the surgeon to visualize the placement of the perforators prior to marking (Figure 3).

Once the perforators have been selected, the patient is marked one day before surgery. Based on the preoperative imaging, a handheld Doppler probe is used to identify and mark the skin perforators (Figure 4). Typically, there are both medial and lateral perforators, but we usually favor the medial perforators because they are easier to harvest in the supine position. The medial perforator usually enters posterior to the gracilis muscle. There have been some situations in which a more posterior and lateral perforator was dominant and therefore used. The superior marking is at the gluteal fold. The inferior marking is less than 6 cm below the superior marking. The flap is designed in a crescent shape so the scar does not extend onto the visible lateral or medial thigh outside of the gluteal fold. Once the marks are drawn, we listen with a hand held doppler to identify the arterial signal.

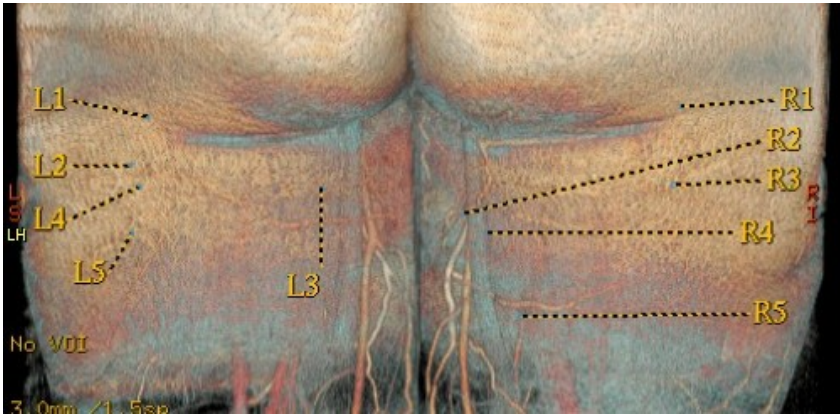


Figure 3. Three-dimensional magnetic resonance angiography (MRA) reconstruction allows the surgeon to visualize perforator placement prior to marking. The best perforator will be chosen on the basis of location and caliber.

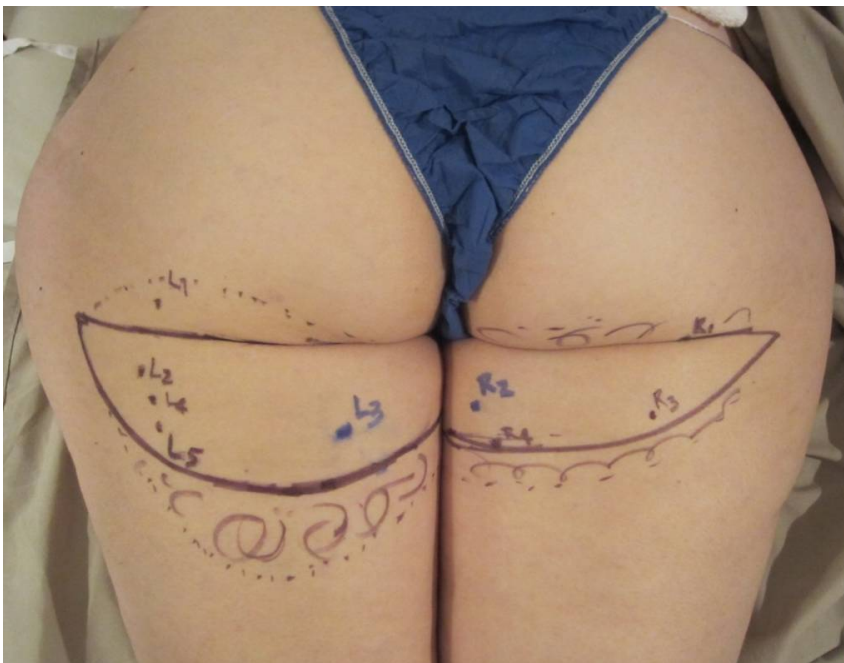


Figure 4. Once the perforators have been selected, we see the patient the day before surgery to apply the marks. Based on the preoperative imaging, the previously identified perforators are transposed onto the patient's body. A handheld Doppler probe is used to confirm and mark the skin perforators one day prior to surgery. The squiggly marks indicate additional fat that will be captured with beveling.

4. Anatomy

The posterior thigh tissue is bordered by the iliotibial tract and adductor muscles horizontally, and the gluteal fold and popliteal fossa vertically. The profunda femoris artery enters the posterior compartment of the thigh and typically gives off three main perforators. The first perforator supplies the adductor magnus and gracilis, and the second and third perforators supply the semimembranosus, biceps femoris, and vastus lateralis.

5. Surgical technique

On the day of surgery each of our patients receive 5000 units of subcutaneous heparin and perioperative intravenous antibiotics. The operation is performed under general anesthesia. Once general anesthesia is administered, the patient is prepped to include the upper thighs into the field. Sequential compression stockings are placed and wrapped with sterile towels and drapes. Flap harvest may be performed in the supine or prone position. The supine frog-leg position offers the advantage of decreased operative time because of rapid dissection from a medial approach and the lack of a need for repositioning. The prone position uses a lateral approach and maintains the possibility of conversion to a transverse upper gracilis flap if no adequate perforators are identified. When the supine approach is used, there is no specific bailout flap, and therefore preoperative imaging is essential.

When in the preferred supine position, the patient's legs are placed in a frog leg position. Using a 10-blade scalpel, the incision is made on the crescent-shaped skin island designed on the thigh down to the subcutaneous fat, and the skin and fat raised above the muscles of the inner thigh. When the most lateral markings need to be incised, the leg is placed medial to access the lateral/posterior thigh region. The leg is placed back into frog leg position and beveling inferior is performed to capture as much fat as possible. In the supine position, the fascia is entered over the gracilis muscle and the vascular pedicle is identified approximately 3 cm posterior to the gracilis muscle. Careful dissection is performed to identify the perforating branch from the profunda femoris artery which supplies the flap with blood. Staying above the fascia until the posterior border of the gracilis is identified, the fascia is incised and the perforator is found in relation to the gracilis muscle. Once the key perforator is identified, standard perforator dissection proceeds to harvest the desired pedicle length and vessel diameter (Figure 5). Creating adequate exposure to ligate the tiny branches that enter the muscle, the pedicle elongates until its caliber is consistent with the internal mammary artery. It is helpful to obtain wide exposure with fish hooks and Gelpi retractors, advancing the Gelpi retractors as the dissection proceeds. The vessel is then followed back toward the main profunda artery to its parent vessel (Figure 6).

After recipient-site preparation, the anastomosis is performed. The internal mammary artery and vein are prepared in the chest and the flap is then harvested, weighed and transferred to the breast. Once on the chest, the PAP flap vessels are anastomosed to the internal mammary vessels using microsurgery. The profunda perforator vein is anastomosed to the internal

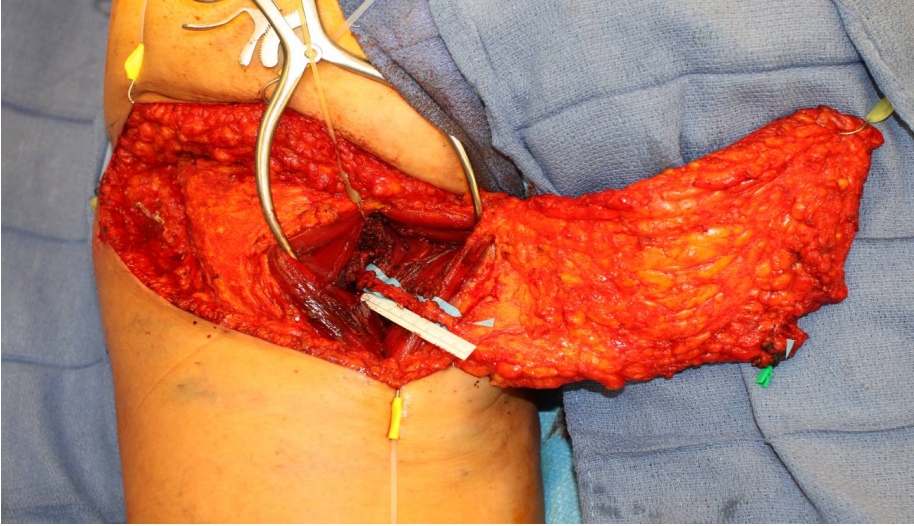


Figure 5. Careful dissection is performed to identify the perforating branch from the profunda femoris artery which supplies the flap with blood. Staying above the fascia until the posterior border of the gracilis is identified, the fascia is incised and the perforator is found in relation to the gracilis muscle. Once the key perforator is identified, standard perforator dissection proceeds to harvest the desired pedicle length and vessel diameter.

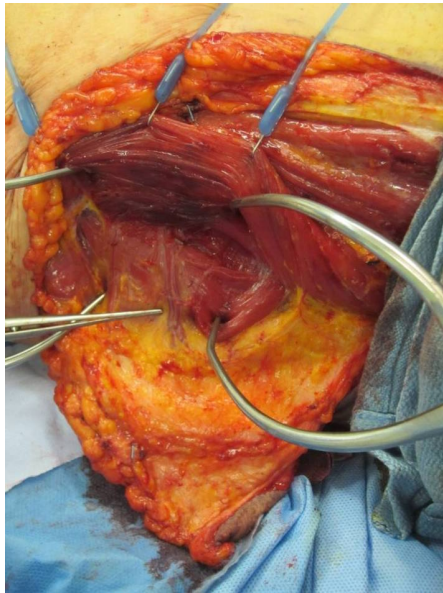


Figure 6. It is helpful to obtain adequate exposure with fish hook retractors and Gelpi retractors, advancing the Gelpi retractors as the dissection proceeds. The vessel is then followed back toward the main profunda artery to its parent vessel.

mammary vein using a venous coupler with sizes ranging from 2.0 to 3.0 mm. The artery is addressed next. Using a 9-0 nylon, the profunda artery is anastomosed to the internal mammary artery with either a continuous suture or interrupted sutures. If the flap is buried, an internal Doppler monitoring device is used. If a skin island is used, an internal Doppler device is usually unnecessary. Either way, the flap is deepithelialized and inset. After blood flow is reestablished, the flap is coned and shaped in a manner similar to the TUG flap for breast reconstruction (Figure 7).

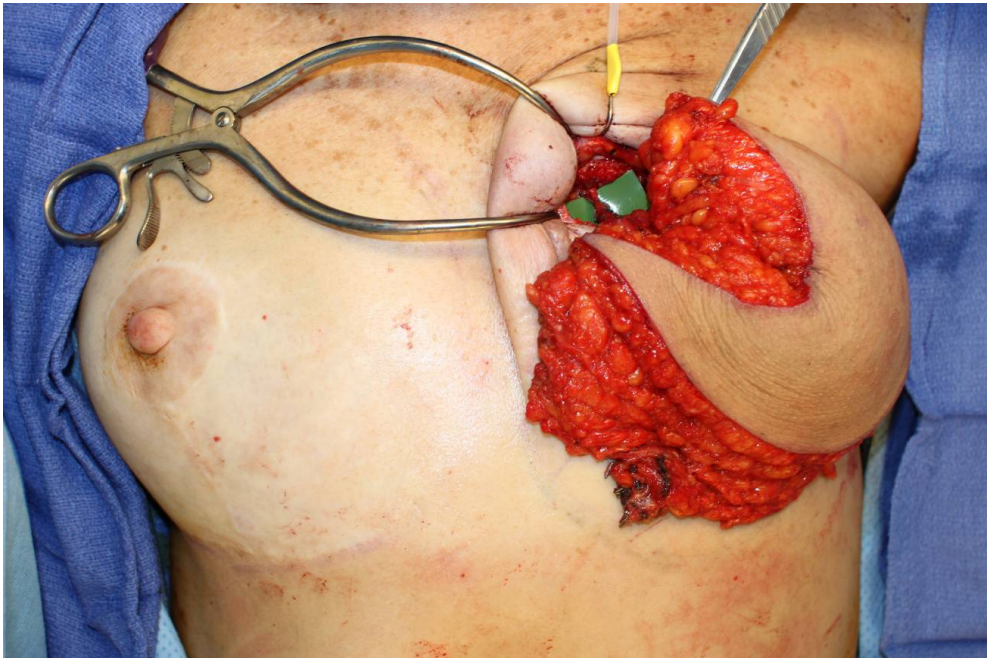


Figure 7. After blood flow is reestablished, the flap is coned and shaped in a manner similar to the TUG flap for breast reconstruction.

The donor site is closed in a multilayer fashion over a drain. Meticulous closure of the posterior thigh donor site must be performed in order to achieve primary wound healing and avoid subsequent wound dehiscence. The superior aspect of the donor site incision needs to be tacked down with 2-0 vicryl to preserve the gluteal crease and to prevent inferior migration of the scar onto the thigh. The postoperative appearance of a PAP flap breast reconstruction creates an uplifted and conical aesthetically pleasing breast shape (Figure 8). The donor site is also usually well-concealed (Figure 9).

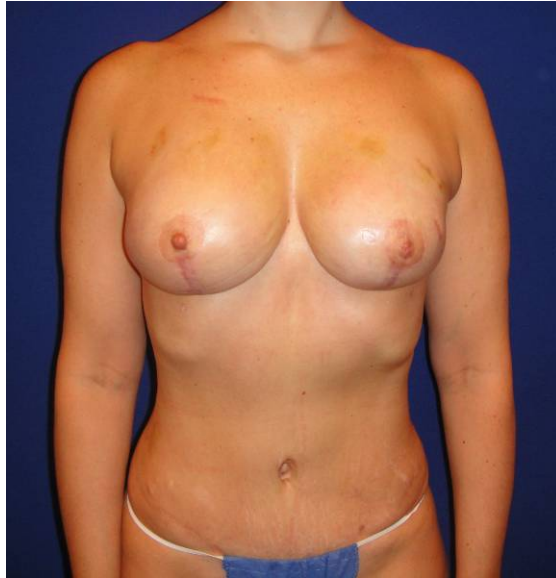

Figure 8. The postoperative appearance of a PAP flap breast reconstruction creates an uplifted and conical aesthetically pleasing breast shape.

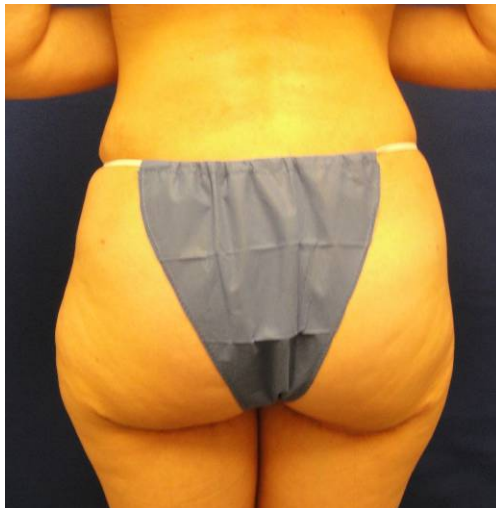

Figure 9. The donor site is also usually well-concealed.

6. Postoperative management

The postoperative care is similar to other perforator flaps such as the DIEP or GAP flaps. On postoperative day one, the Foley catheter, blood pressure cuff, oxygen, and intravenous fluids are discontinued. Patients may start a regular diet. Pain is usually well-controlled by oral medications. Although the patient may ambulate or sit with minimal discomfort, strenuous exercise should be avoided for 6-8 weeks. Patients usually stay in the hospital 3-4 days to monitor the blood flow into the free flap. When discharged, the patient may walk without difficulty, but some have reported temporary tightness in the posterior thigh. Other potential complications include posterior thigh numbness, donor site dehiscence, seroma, hematoma, takeback, flap loss and other potential complications of microvascular surgery.

7. Discussion

Most microsurgeons who perform autologous tissue breast reconstruction select the abdomen as their first choice in donor site. We agree with this choice; we also prefer the abdomen as our primary donor site for autologous tissue breast reconstruction. Our second choice donor site for microsurgical breast reconstruction, however, is the posterior thigh. Like the abdomen, the posterior thigh donor site does not require positioning changes during the operative procedure. The patient can remain supine for both flap harvest and inset, which minimizes the anesthesia time for the patient. Finally, patients report minimal pain at the donor site. Anecdotally, they seem to ambulate and mobilize earlier than patients who undergo abdominal flap harvest.

The advantage to the PAP flap is a natural shape with ample volume in most cases. The scar is usually well-concealed when wearing a bathing suit. The pedicle length usually ranges from 8-10 cm, and is a good size match to the internal mammary vessels. Disadvantages include possible inferior location of the perforator causing the scar to be placed lower on the thigh in a more conspicuous position. This may be revised in a secondary procedure to raise the scar so that it is camouflaged in the gluteal fold. In very large-breasted women, the posterior thigh donor site may not be adequate. In such cases, additional procedures used to obtain volume such as fat grafting or rotational flaps may also be performed at a second stage.

Developments in radiographic imaging have supported preoperative flap design and planning. The ability to identify perforators preoperatively has decreased the level of difficulty for perforator flaps. Intraoperative flap elevation is now more predictable and straightforward, which makes dissection faster and easier. Hypothetically, easier perforator flap dissection should also lead to a lower complication rate. We feel that the PAP flap is a viable technique for autologous tissue breast reconstruction that may be easier to master than the traditional GAP procedures. In conclusion, we recommend the PAP flap as a simple and reliable approach to perforator flaps for microsurgical breast reconstruction.

Author details

Constance M. Chen MD, MPH, FACS^{1,2,3}, Maria LoTempio MD^{1,2,3} and Robert J. Allen MD, FACS^{1,3,4}

1 Plastic & Reconstructive Surgery, New York Eye & Ear Infirmary, New York, NY, USA

2 Plastic & Reconstructive Surgery, Lenox Hill Hospital, New York, NY, USA

3 Plastic & Reconstructive Surgery, New York Downtown Hospital, New York, NY, USA

4 Institute of Reconstructive Plastic Surgery, NYU Medical Center, New York, NY, USA

Authors declare no financial interest or commercial association with information submitted in manuscript. No products, devices, or drugs were used or identified in the manuscript.

References

- [1] Hurwitz, D. J. Closure of a large defect of the pelvic cavity by an extended compound myocutaneous flap based on the inferior gluteal artery. *Br J Plast Surg* (1980). , 33, 256-261.
- [2] Angrigiani, C, Grilli, D, & Thorne, C. H. The adductor flap: a new method for transferring posterior and medial thigh skin. *Plast Reconstr Surg* (2001). , 107, 1725-1731.
- [3] Song, Y. G, Chen, G. Z, & Song, Y. L. The free thigh flap: a new free flap concept based on the septocutaneous artery. *Br J Plast Surg* (1984). , 37, 149-159.
- [4] Saint-Cyr, M, Schaverien, M, Arbique, G, et al. Three- and four-dimensional computed tomographic angiography and venography for the investigation of the vascular anatomy and perfusion of perforator flaps. *Plast Reconstr Surg* (2008). , 121, 772-780.
- [5] Alonso-Burgos, A, Garcia-Tutor, E, Bastarrika, G, et al. Preoperative planning of deep inferior epigastric artery perforator flap reconstruction with multislice-CT angiography: imaging findings and initial experience. *J Plast Reconstr Aesthet Surg* (2006). , 59, 585-593.
- [6] Rosson, G. D, Williams, C. G, Fishman, E. K, et al. D CT angiography of abdominal wall vascular perforators to plan DIEAP flaps. *Microsurgery* (2007). , 27, 641-646.
- [7] Neil-Dwyer, J. G, Ludman, C. N, Schaverien, M, et al. Magnetic resonance angiography in preoperative planning of deep inferior epigastric artery perforator flaps. *J Plast Reconstr Aesthet Surg*(2008).

- [8] Chernyak, V, Rozenblit, A. M, Greenspun, D. T, et al. Breast Reconstruction with Deep Inferior Epigastric Artery Perforator Flap: 3.T Gadolinium-enhanced MR Imaging for Preoperative Localization of Abdominal Wall Perforators. *Radiology*(2008). , 0.
- [9] Tuinder, S, Van Der Hulst, R, Lataster, A, et al. Superior gluteal artery perforator flap based on septal perforators: preliminary study. *Plast Reconstr Surg* 122: 146e-148e, (2008).

